

Last revision: October 2011 by Luis Arias

Fluorescein Angiography

Authors:

Luis Arias, MD
Hospital Universitari de Bellvitge - University of Barcelona. Spain

Jordi Monés, MD
Institut de la Màcula i de la Retina - Centro Médico Teknon - Barcelona. Spain

Introduction

Fluorescein angiography (FA) was introduced in ophthalmology by Novotny and Alvis in the sixties of the last century.

They took serial fundus photographs after intravenous injection of sodium fluorescein to study the retinal and choroidal circulation⁽¹⁾.

Initially, they used this technique in diabetic and hypertensive patients and after, the technique was used in age-related macular degeneration (AMD).

Although the clinical diagnosis of AMD can be established based on patient's history and fundus examination, FA is the most important ancillary test for classifying the disease in its different subtypes, especially in its wet form.

Nowadays, optical coherence tomography (OCT) is being more used than FA for monitoring the response to treatment, although FA is still very useful in some cases. Sodium fluorescein is a small molecule, with a molecular weight of 376.27 daltons, and it is highly soluble in water.

It is stimulated by light in the range of 465-490 nm and then it enters into a higher energy state.

The molecule emits longer wavelength fluorescence, between 520 and 530 nm, as it decays to a lower energy state.

In clinical application, two filters are used.

An excitation filter allows the passage of blue light, which stimulates the fluorescein in the eye, which emits yellow-green light.

In addition, a barrier filter is used to block some reflected blue light, allowing only the yellow-green light to pass through.

This resultant fluorescence is recorded by a camera as an image⁽²⁾.

Sodium fluorescein diffuses through the fenestrated vessels of the choriocapillaris, but does not cross the internal and the external blood-retinal barriers.

Thus, any condition that compromises these barriers, obstructs blood flow, or changes the normal pigmentation of the retinal pigment epithelium (RPE) can cause abnormalities on FA.

The dye is removed from the vascular compartment by the kidney.

It is relatively inert, making intravenous injection safe and severe adverse reactions rare. Nevertheless, the patient should be properly informed of the potential risks of FA injection⁽³⁾.

Interpretation

Several FA patterns can be observed in AMD patients.

They can be classified at those leading to decreased fluorescence (hypofluorescence) or increased fluorescence (hyperfluorescence).

Hypofluorescence either represents blocked fluorescence or a vascular filling defect ([Table 1](#)).

Hypofluorescence
Blocked
<ul style="list-style-type: none">• Intraretinal or subretinal hemorrhage/exudate• Sub-RPE hemorrhage• Pigment proliferation• Pigment epithelial clumping (RPE rip)
Vascular filling defect
<ul style="list-style-type: none">• Choroidal vascular atrophy• Retinal capillary occlusion

Table 1 - Causes of hypofluorescence.

Hyperfluorescence can be the result of loss of the normal barrier to background choroidal fluorescence known as transmitted fluorescence.

A second reason for hyperfluorescence can arise from extravascular accumulation of the dye or from leakage from abnormal vessels ([Table 2](#))⁽⁴⁾.

Hyperfluorescence
Transmitted fluorescence
<ul style="list-style-type: none">• RPE atrophy• RPE rip• Hard, basal laminar drusen
Extravascular fluorescence
<ul style="list-style-type: none">• Serous pigment epithelial detachment• Soft drusen• Disciform scar• Loculated fluid• Cystoid macular edema
Abnormal vessels
<ul style="list-style-type: none">• Choroidal neovascularization• Retinal angiomatous proliferation

Table 2 - Causes of hyperfluorescence.

By convention, leakage of fluorescein into a space is referred to as pooling, while leakage into a tissue is called staining⁽⁵⁾.

Angiographic patterns in AMD

Drusen and RPE abnormalities

The majority of patients with AMD have drusen and RPE abnormalities with no significant visual loss.

FA is not usually indicated in these cases unless we suspect the presence of choroidal neovascularization (CNV).

Several types of drusen can be identified. Hard drusen are small (<63 μm), round, well-defined, yellowish deposits that correspond to accumulation of hyaline material in the inner and outer collagenous zones of Bruch's membrane.

On FA, they appear hyperfluorescent as transmission defects due to overlying RPE thinning⁽⁶⁾.

On occasion there may be a myriad of small drusen, termed cuticular or basal laminar drusen, which appear as a "starry sky" on FA (Figure 1).

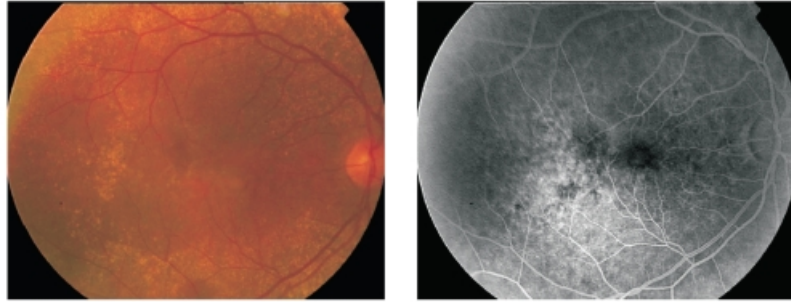


Figure 1 - Cuticular drusen with the typical pattern of "starry sky"

Soft drusen are larger (>63 μm) with poorly defined borders and they tend to coalesce and become confluent.

Their angiographic appearance depends on the thinning of the overlying RPE, the histochemical composition and the age of the patient.

They are hyperfluorescent with phospholipid accumulation and in younger patients⁽⁷⁾.

Soft drusen represent localized detachments of the RPE.

It is very usual to find both hard and soft drusen in the same eye of a patient (Figure 2).

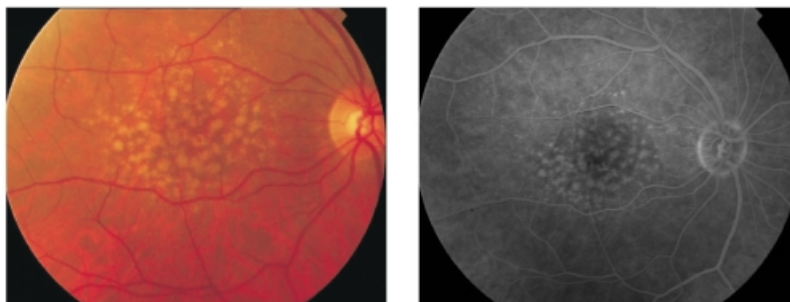


Figure 2 - Coexistence of hard and soft drusen in the same eye of a patient with AMD.

The confluence of soft drusen can produce a drusenoid pigment epithelial detachment (PED), which shows hyperfluorescence and dye pooling without leakage beyond its margin with typical areas of focal hyperpigmentation (Figure 3).

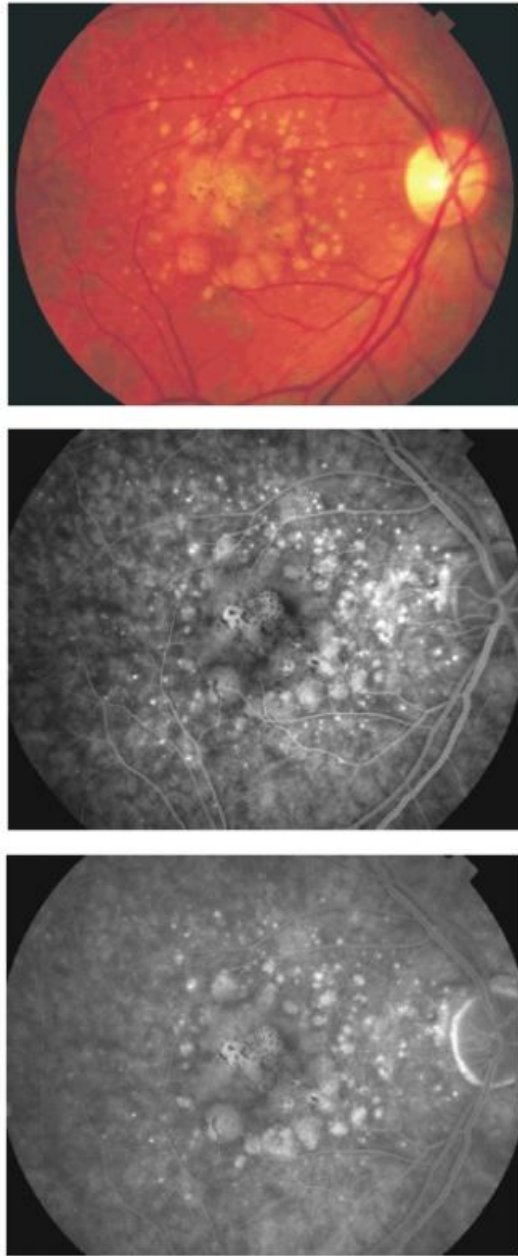


Figure 3 - Drusenoid pigment epithelial detachment.

In addition to drusen we can find RPE abnormalities, namely hyperpigmentation.

Focal hyperpigmentation is a risk factor for the development of choroidal neovascularization (CNV) and angiographically appears as a blocked fluorescence (Figure 4).

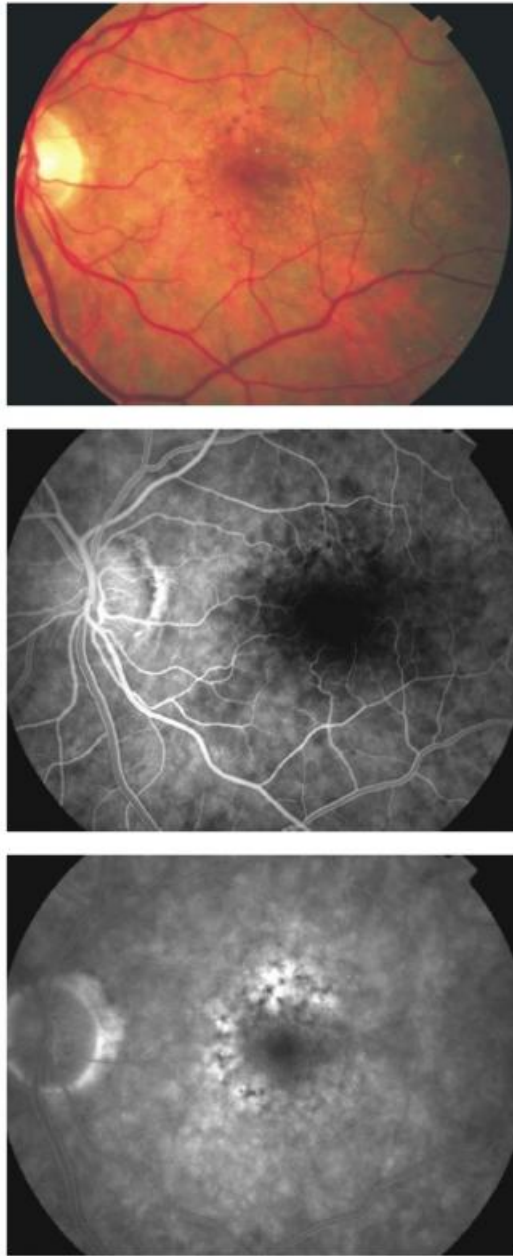


Figure 4 - RPE abnormalities with focal hyperpigmentation.

Histopathologically it is characterized by focal RPE hypertrophy and pigment migration into the subretinal space.

It also displays focal hyperautofluorescence suggesting that these cells contain lipofuscin⁽⁸⁾.

Atrophic AMD

Atrophy can occur in sharply defined areas of severe atrophy, known as geographic atrophy (GA), or in less well-defined, more granular regions of less severe atrophy, known as non-GA.

Both forms share the feature of RPE loss, more extensive and with associated atrophy of the overlying retina and underlying choriocapillaris in GA.

The angiographic appearance depends on the remaining pigment within the RPE and choriocapillaris vessels.

Non-GA shows mottled early hyperfluorescence, which fades late consistent with window defect (Figure 5).

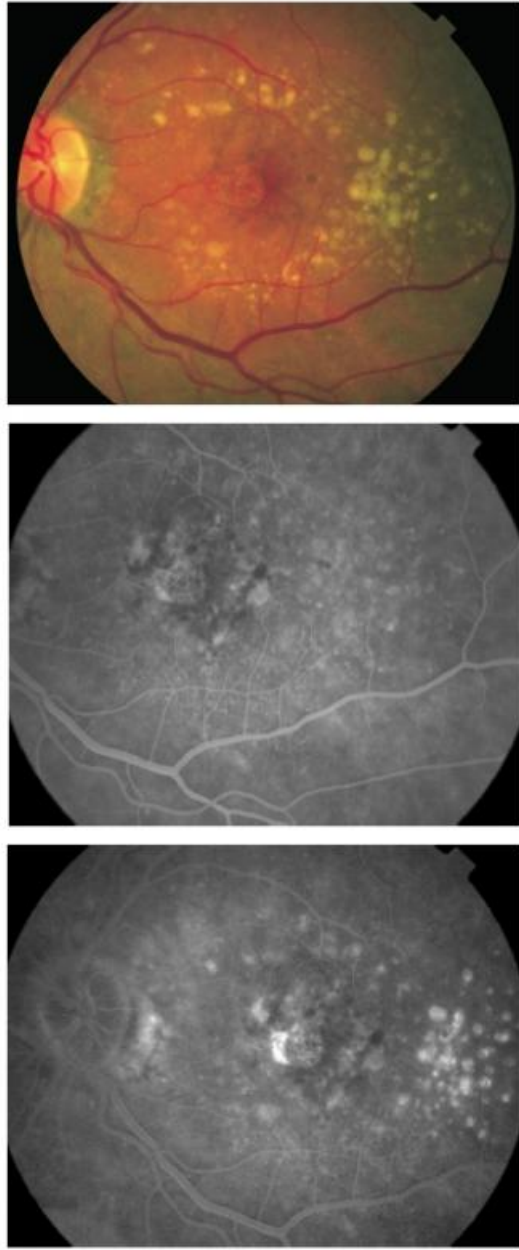


Figure 5 - Non-geographic atrophy.

GA typically shows late well-defined hyperfluorescence from staining of the exposed deep choroid and sclera⁽⁹⁾.

In these cases, visual acuity depends on the foveal involvement (Figure 6).

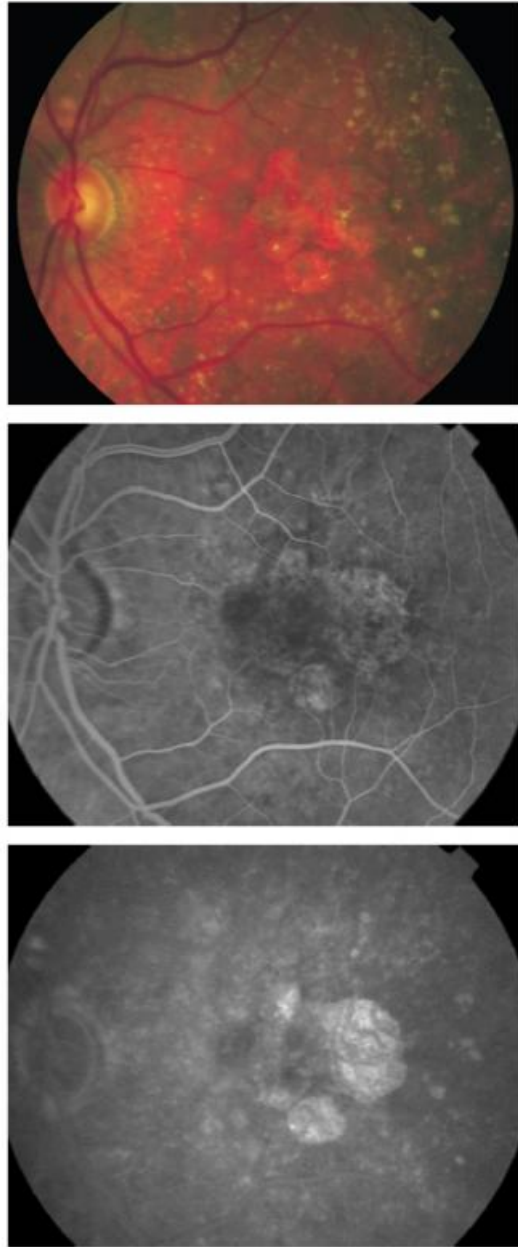


Figure 6 - Geographic atrophy.

In advanced cases, larger choroidal vessels show a sclerotic appearance (Figure 7).

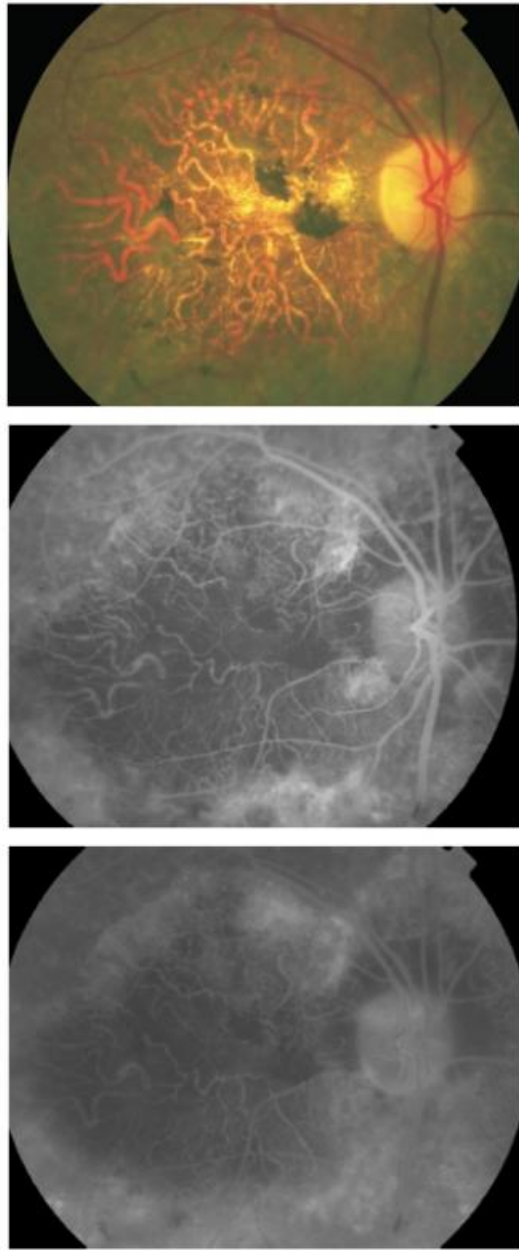


Figure 7 - Severe atrophic AMD with sclerotic appearance of larger choroidal vessels.

Classic CNV

Classic CNV is characterized by well-demarcated hyperfluorescence in early phases on FA and late leakage that obscures the boundaries of the lesion (Figure. 8).

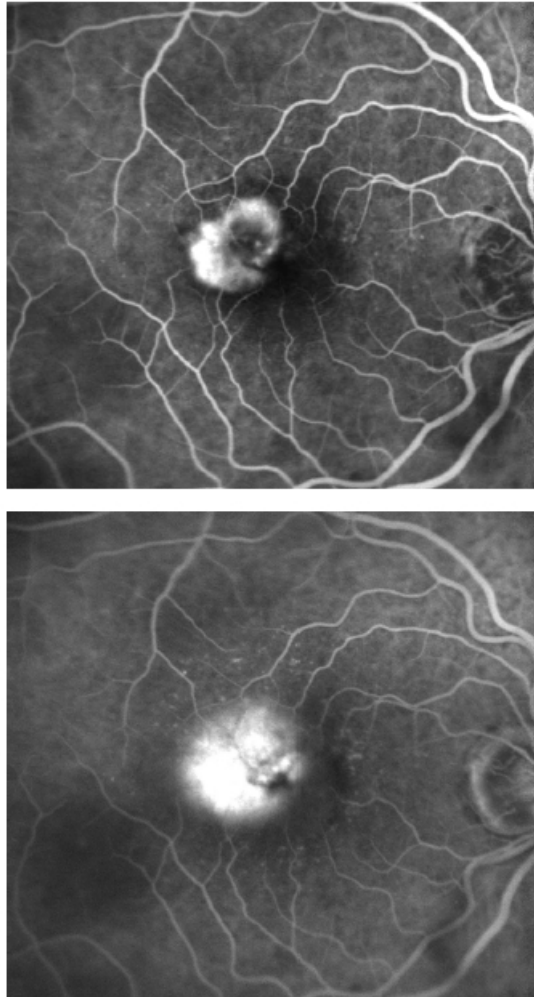


Figure 8 - Classic CNV.

As defined by Donald Gass, classic CNV lies between the neurosensory retina and the RPE (type II CNV)[\(10\)](#).

Angiographic classic CNV appears as a lacy or bicycle-wheel pattern.

Depending on its location, it can be classified as extrafoveal (>200 microns from the foveal center) (Figure 9), juxtafoveal (1-199 microns from the foveal center) (Figure 10) or subfoveal (involving the foveal center) (Figure 11).

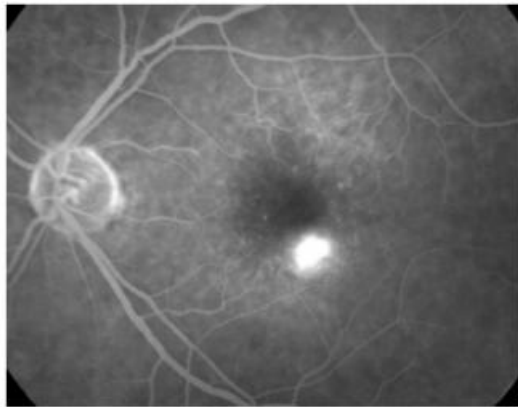
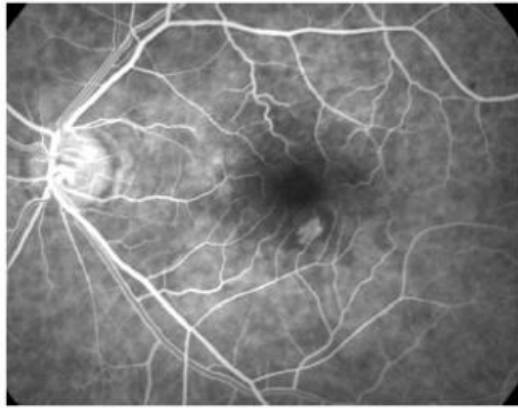
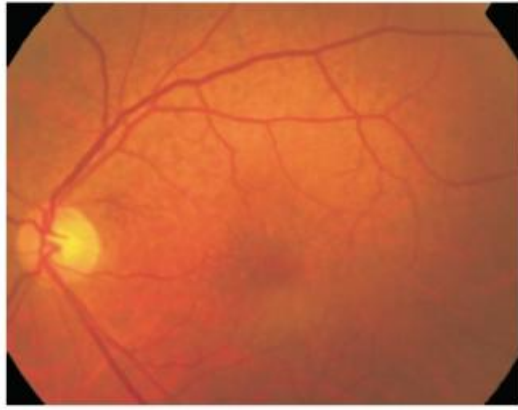


Figure 9 - Extrafoveal classic CNV.

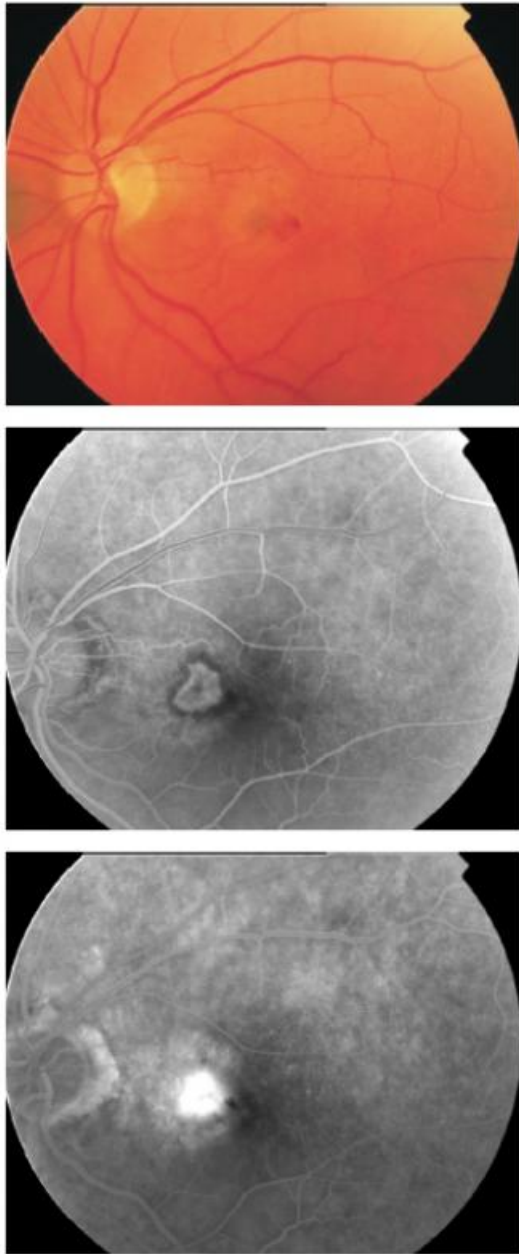


Figure 10 - Juxtafoveal classic CNV.

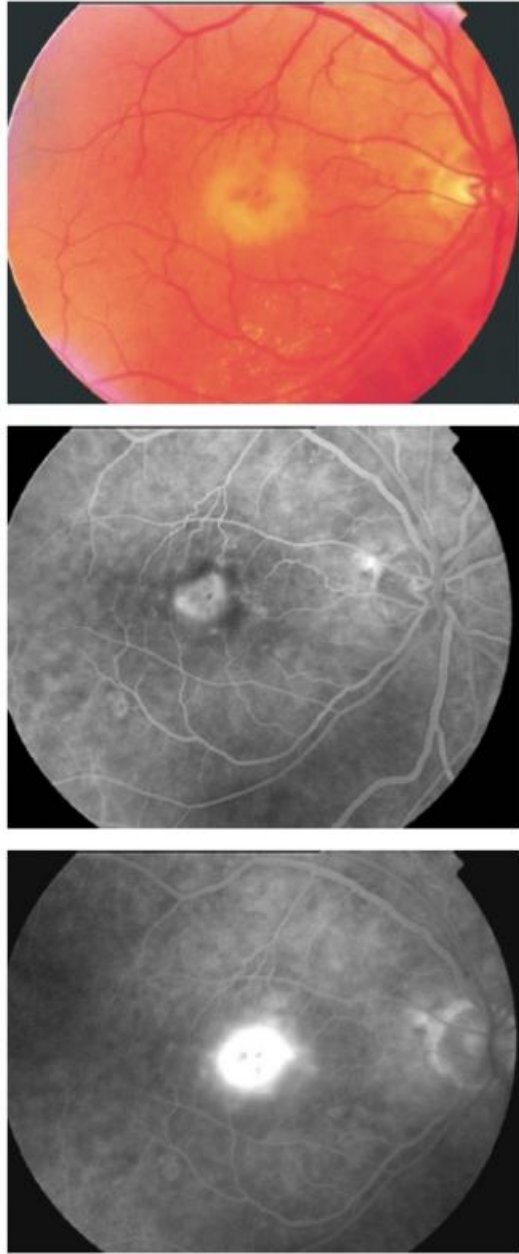


Figure 11 - Subfoveal classic CNV.

Sometimes, a feeder vessel can be localized (Figure 12).

Another typical feature is the presence of a hyperpigmented rim, hypofluorescent on FA, surrounding the CNV (Figure 12).

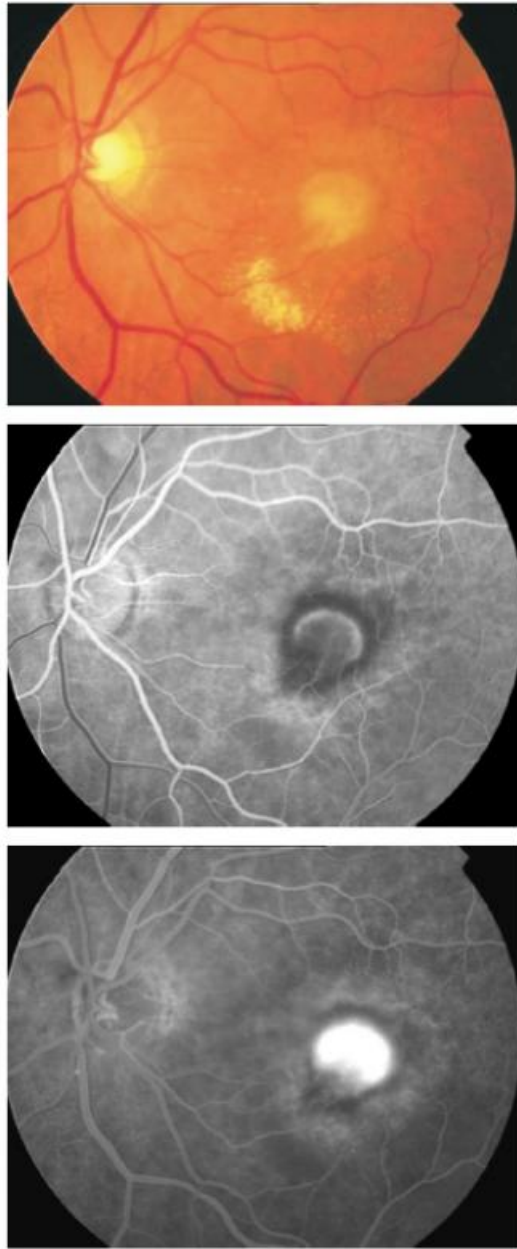

Figure 12 - Classic CNV with feeder vessel.

On occasion, classic CNV can be associated to loculated fluid (Figure 13).

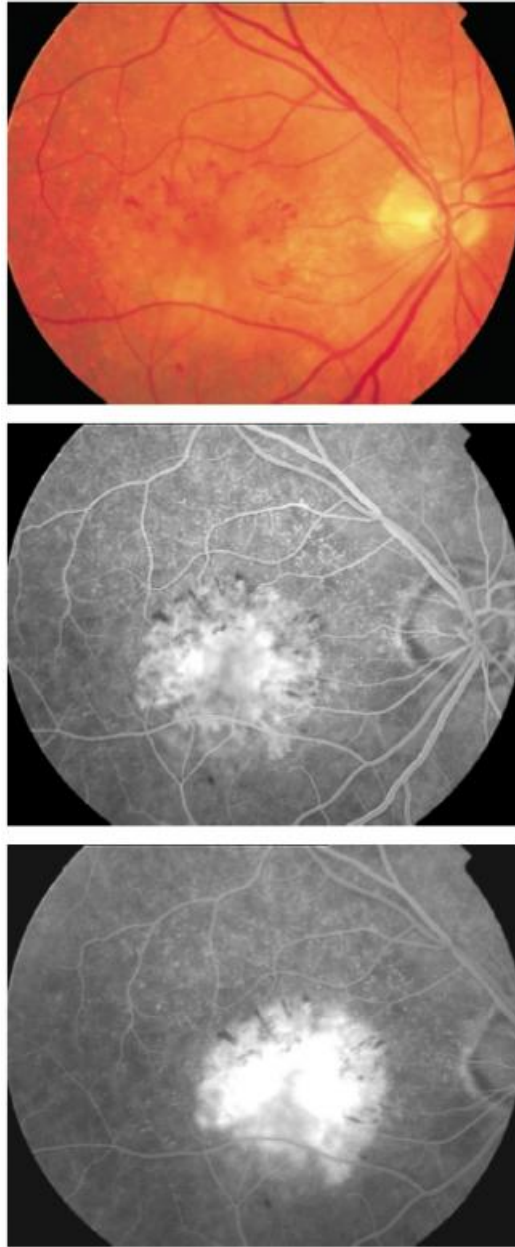


Figure 13 - Classic CNV with loculated fluid.

In loculated fluid, dye pooling is well-demarcated in a confined space of a localized sensory retinal detachment or within intraretinal cystic spaces.

It was a common finding in patients with new subfoveal CNV in the Macular Photocoagulation Study (MPS) and may confuse the treating physician as to the boundary of the lesion⁽¹¹⁾.

Depending on their sizes, classic CNV can be classified as small (Figure 9-11) or medium (Figure 14) or large (Fig. 15).

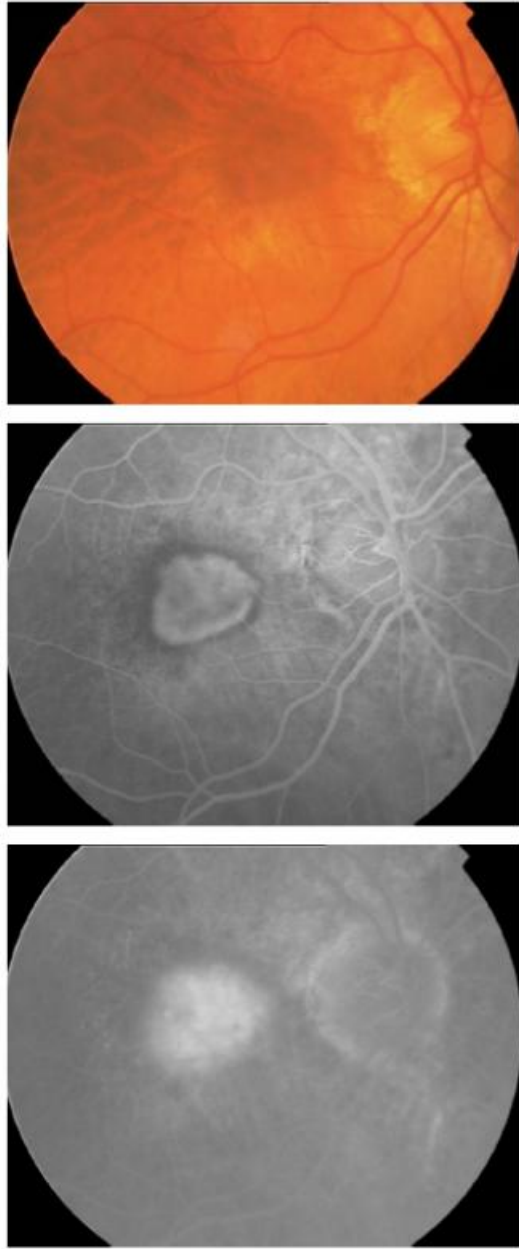


Figure 14 - Medium size classic CNV.

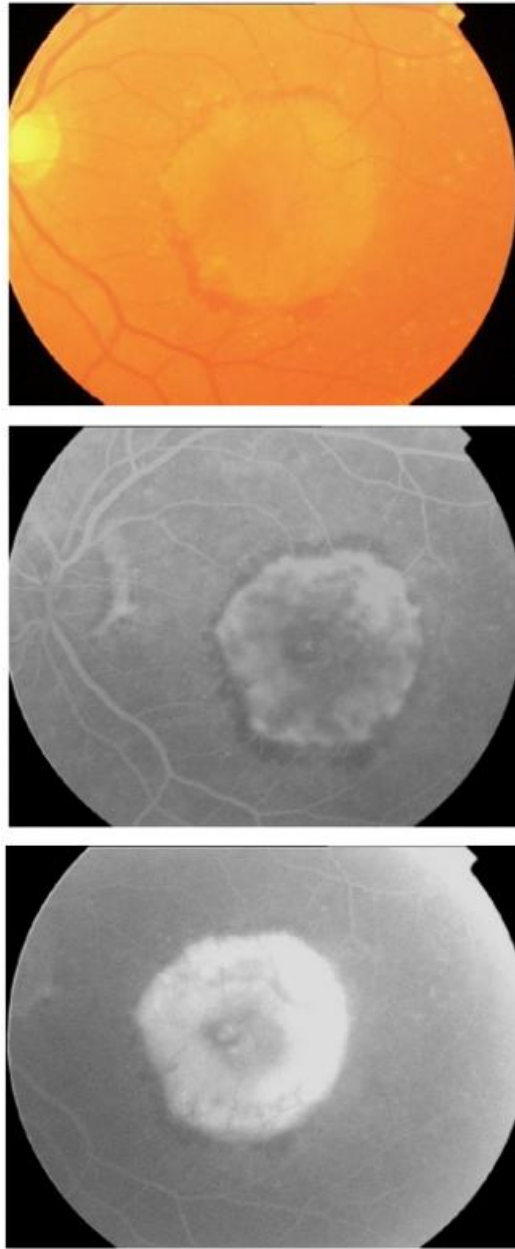


Figure 15 - Large classic CNV.

Importantly, larger classic CNV are associated to a poorer visual prognosis since they represent long-term duration of the pathological disorder.

Classic CNV is an emergency and it requires early treatment to halt the progression of the disease.

Without treatment, CNV tend to enlarge and irreversible fibrosis appears (Figure 16).

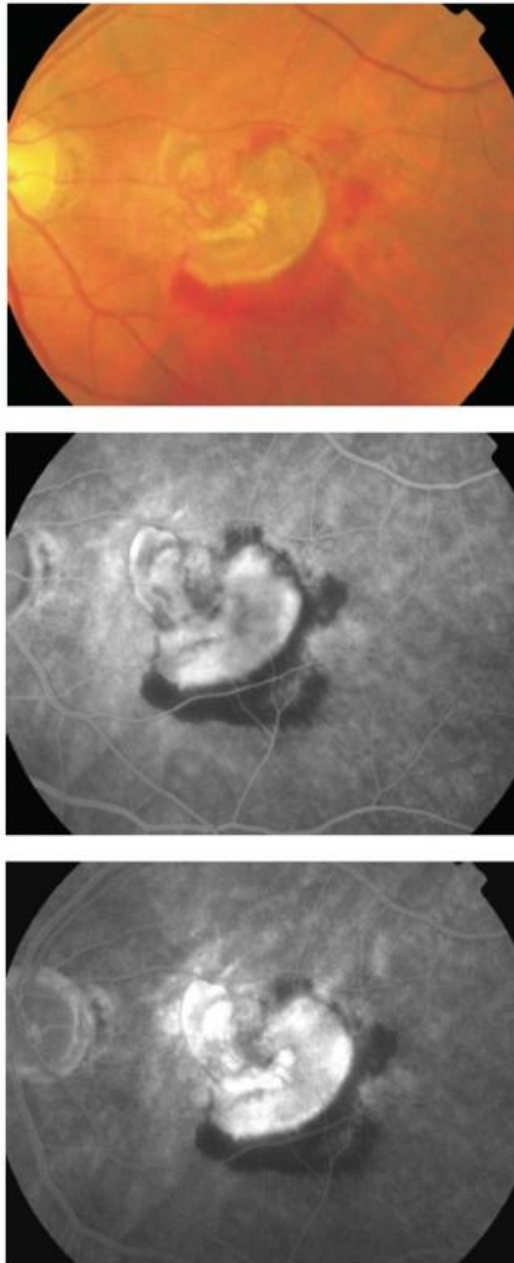


Figure 16 - Old classic CNV with fibrosis.

In the last decade of the last century, the advent of photodynamic therapy (PDT) with verteporfin promoted a classification of the lesions depending on the percentage of classic CNV.

Thus, predominantly classic lesions were defined as having 50% or more of the total lesion size comprised of classic CNV (Figure 17).

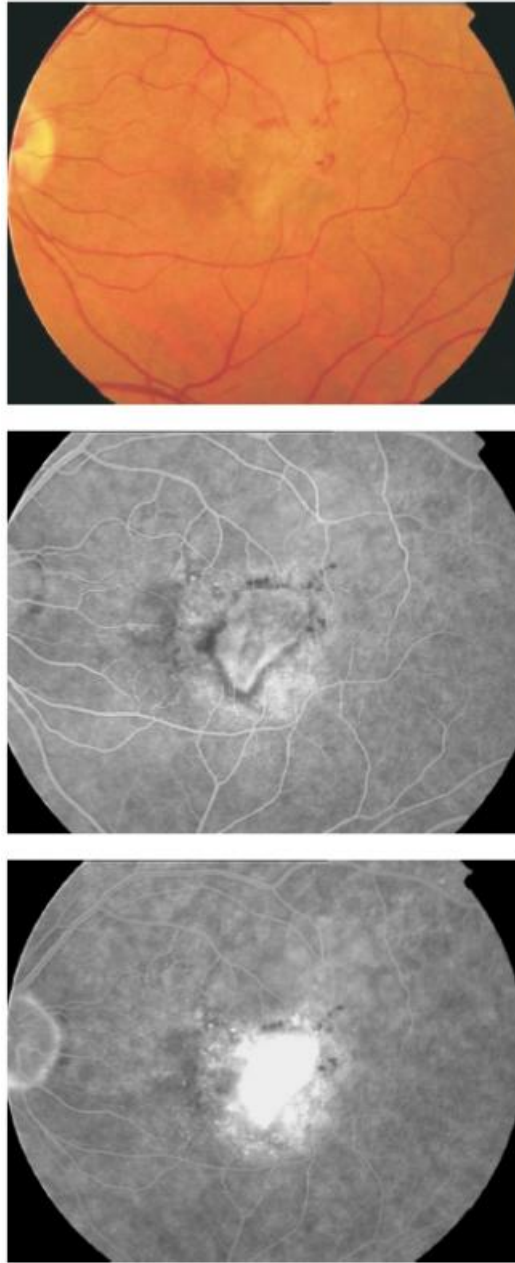


Figure 17 - Predominantly classic CNV.

On the other hand, minimally classic lesions were characterized by classic CNV occupying less than 50% of the total lesion size (Figure 18)[\(12\)](#).

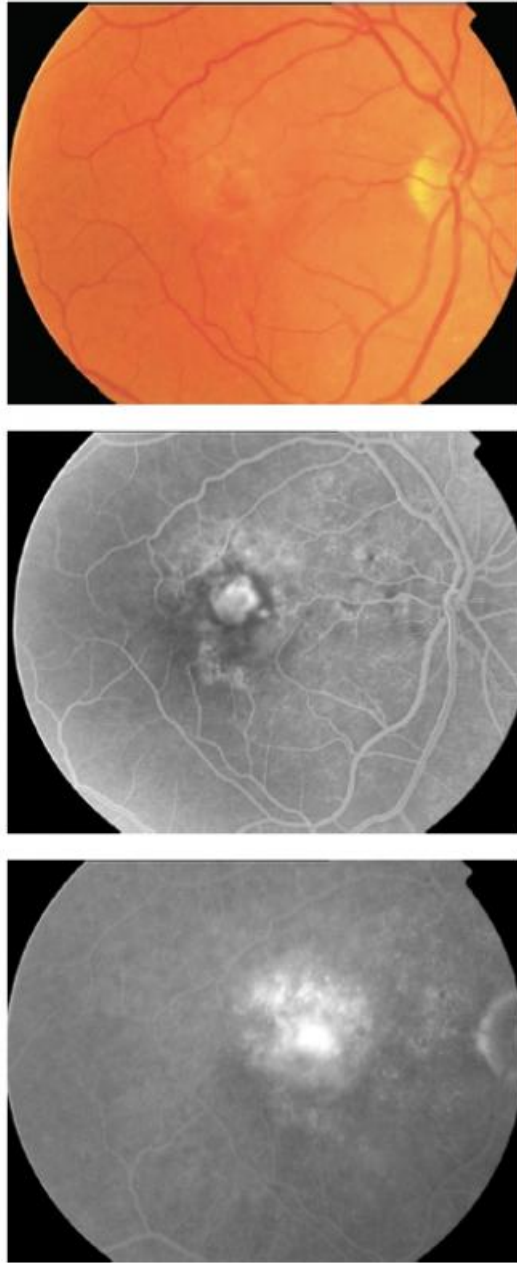


Figure 18 - Minimally classic CNV.

The best results with PDT in wet AMD patients were obtained in the treatment of predominantly classic lesions.

Nowadays, in the antiangiogenic therapy era, this classification has lost popularity among ophthalmologists since lesion composition does not seem to be as relevant as it was with PDT.

Lesion components associated with neovascular AMD that can obscure the boundaries of CNV include changes that block fluorescence, such as blood, fibrous tissue, RPE hyperplasia, or RPE redundancy (from an RPE tear).

Likewise, CNV can be obscured by greater fluorescence from staining or pooling.

Occult CNV

Occult CNV has been categorized as fibrovascular PED or late leakage of undetermined source⁽¹³⁾.

Fibrovascular PED (type I occult CNV) is defined as an irregular elevation of the RPE associated with stippled hyperfluorescence apparent 1 to 2 minutes after fluorescein injection and ill-defined staining or leakage in the late frames (Figure 19-20).

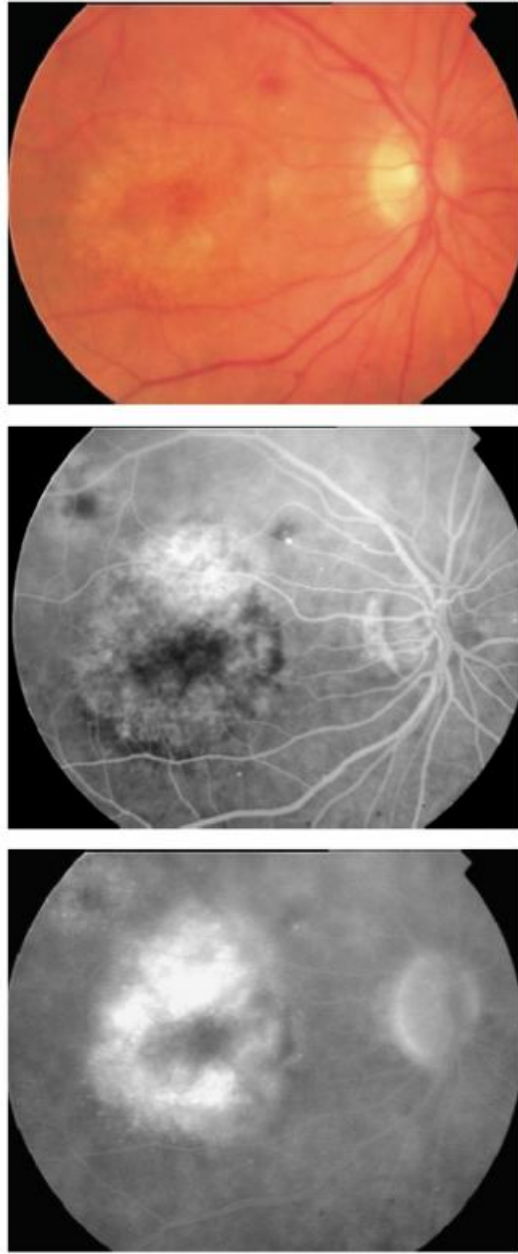


Figure 19 - Fibrovascular PED (type I occult CNV).

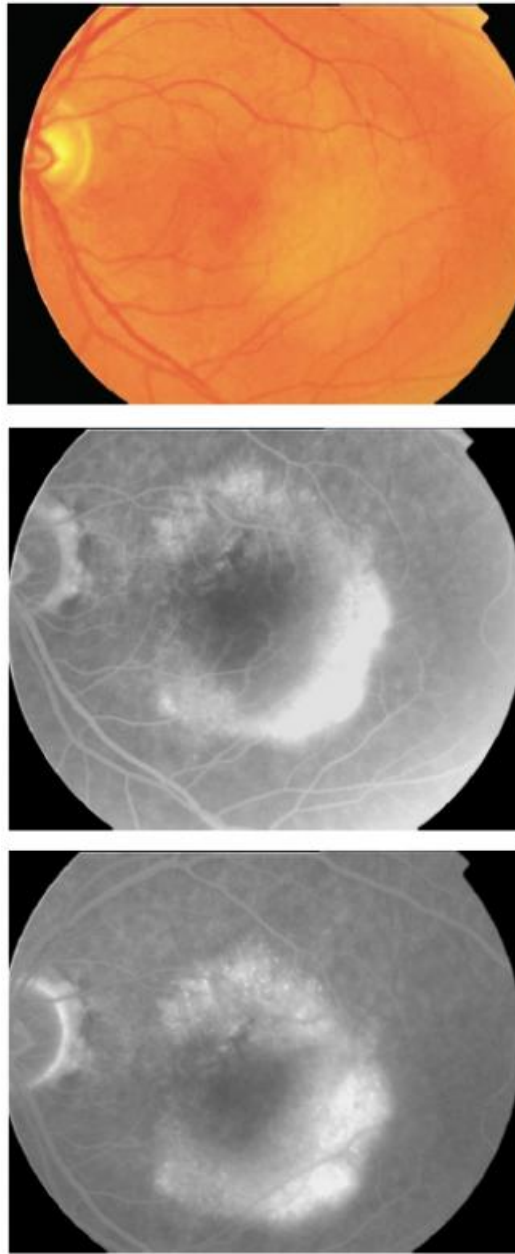


Figure 20 - Fibrovascular plaque

It differs from classic CNV in that the early hyperfluorescence is not as bright and the boundaries usually are indeterminate.

Late leakage of undetermined source (type II occult CNV) lacks a discernible, well-demarcated area of leakage in the early angiographic frames.

Speckled hyperfluorescence with no visible source becomes apparent 2 to 5 minutes after dye injection (Figure 21).

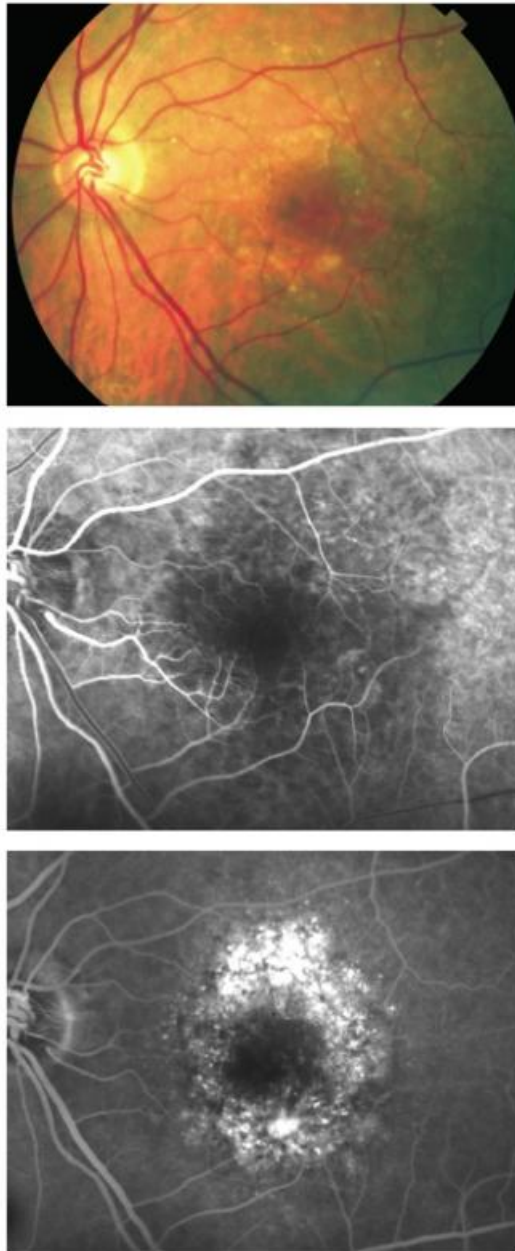


Figure 21 - Late leakage of undetermined source (type II occult CNV).

Serous PED

Although serous PEDs can occur in the context of non-neovascular AMD, most of them are related to CNV.

On fundus biomicroscopy, a serous PED appears as a round or oval translucent elevation of the RPE.

On FA, it is characterized by progressive and uniform hyperfluorescence from early frames with intense pooling of fluorescein in late phases (Figure 22).

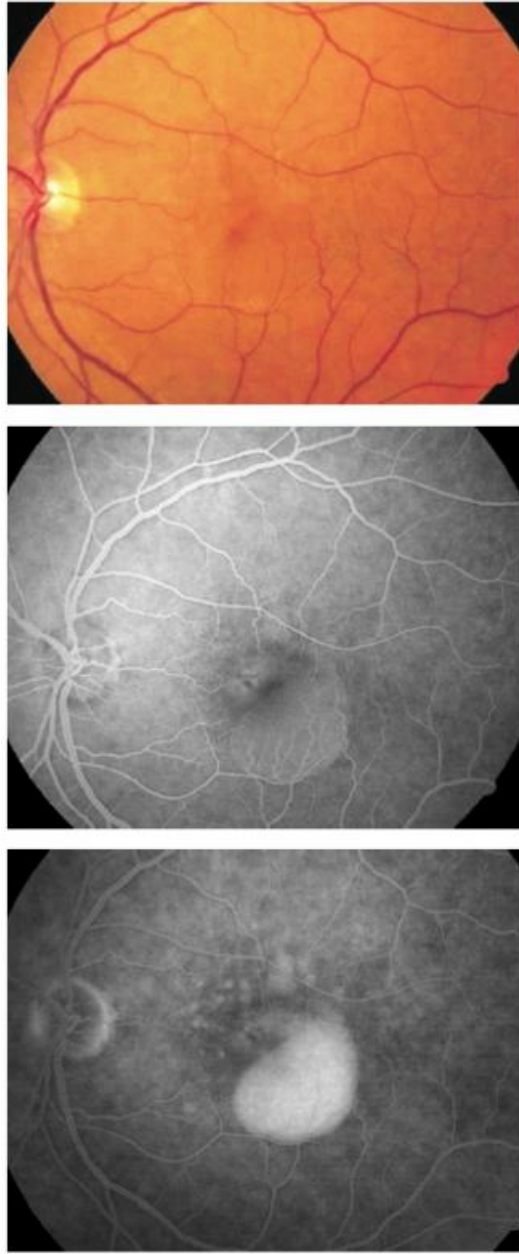


Figure 22 - Serous PED.

PEDs with a notch usually have occult CNV in the notch (Figure 23).

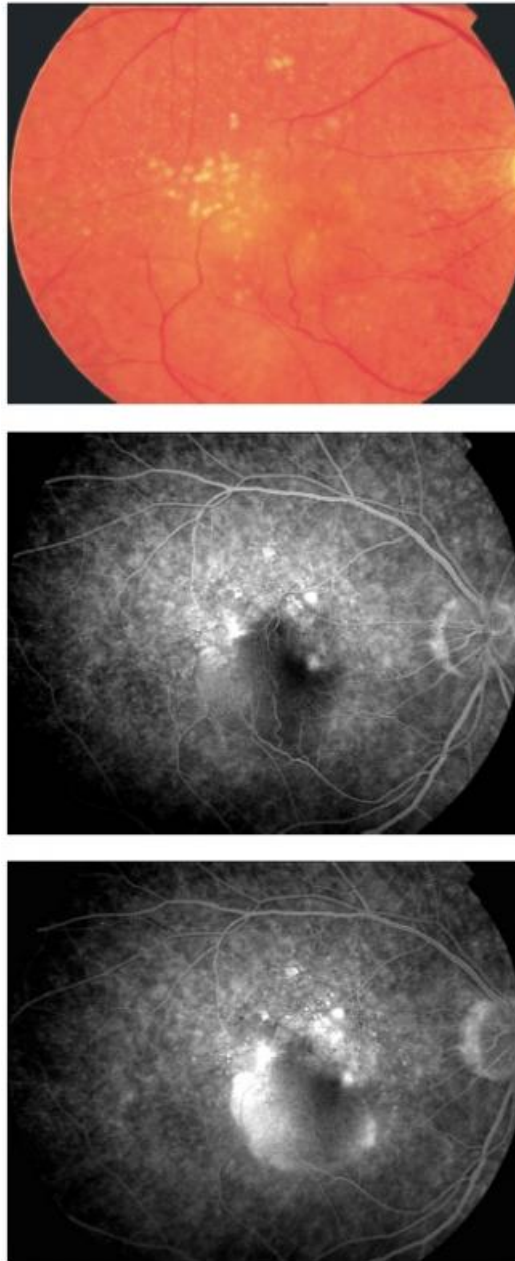


Figure 23 - Serous PED associated to occult CNV.

The association of occult CNV and a serous PED is frequently termed “vascularized PED”[\(14, 15\)](#).

On occasion, a serous PED is associated to classic CNV (Figure 24).

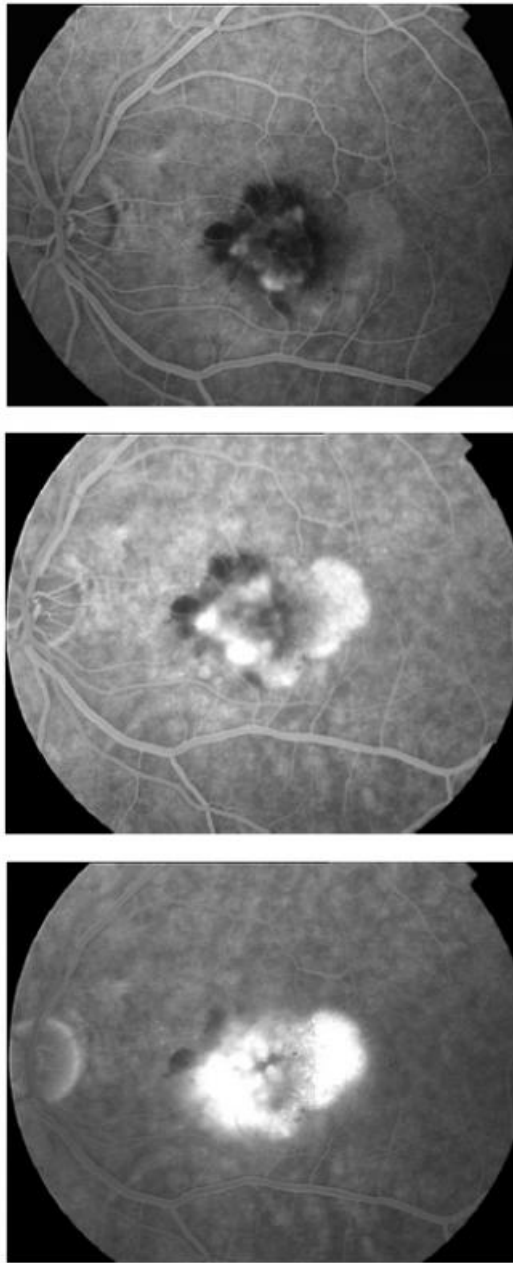


Figure 24 - Serous PED associated to classic CNV.

Retinal angiomatous proliferation

Retinal angiomatous proliferation (RAP) has been described and classified by Yannuzzi et al.[\(16\)](#).

In RAP, the vasogenic process originates in the retina and begins as intraretinal neovascularization (stage I), which progresses to subretinal neovascularization (stage II) and finally to CNV (stage III).

In some cases it is possible to find a retinal-retinal anastomosis.

Angiographically, early lesions (stage I) show a focal area of intraretinal hyperfluorescence with indistinct borders corresponding to the intraretinal neovascularization and surrounding intraretinal edema (Figure 25).

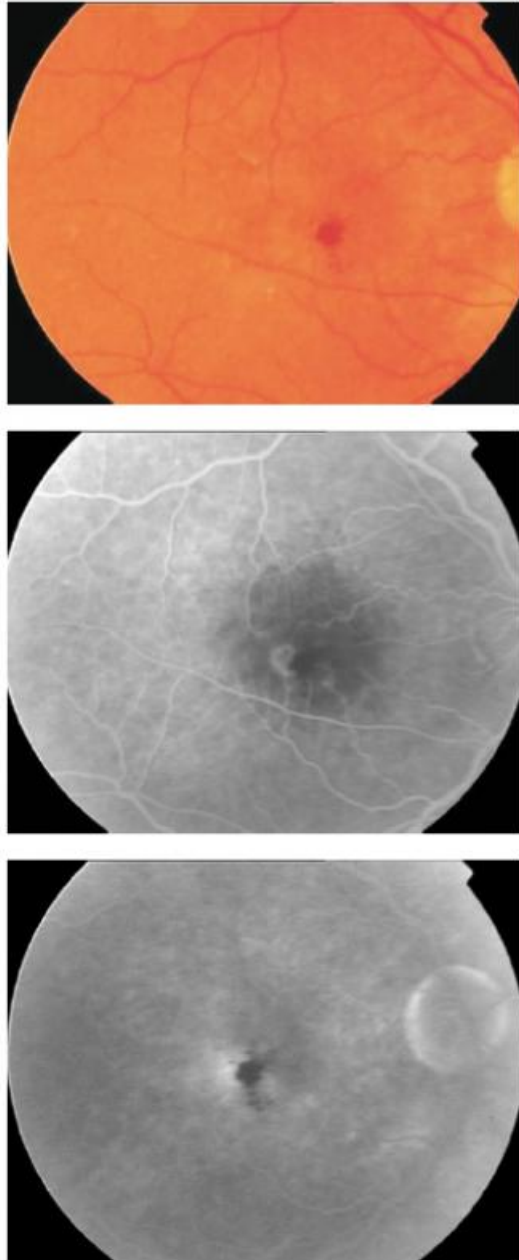


Figure 25 - RAP (stage I).

Sometimes, these early lesions can mimic the appearance of a classic CNV. Later stages of RAP are often classified as minimally classic or occult CNV.

In stage II, it is very characteristic to find a serous PED with occult CNV associated to overlying cystoid macular edema (Figure 26).

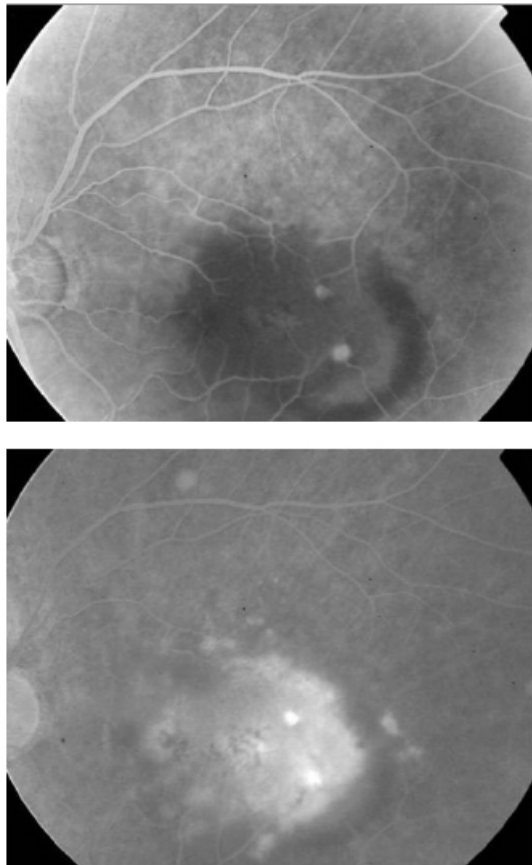


Figure 26 - RAP (stage II).

Indocyanine green (ICG) angiography is often more useful than FA for the diagnosis and evaluation of RAP lesions.

Polypoidal Choroidal Vasculopathy

In polypoidal choroidal vasculopathy (PCV), the primary abnormality involves the choroidal circulation, and the characteristic lesion is an inner choroidal vascular network of vessels ending in an aneurismal bulge.

Clinically, PCV is associated with multiple, recurrent, serosanguineous detachments of the RPE and neurosensory retina secondary to leakage and bleeding from the choroidal vascular lesion⁽¹⁷⁾(Figure 27).

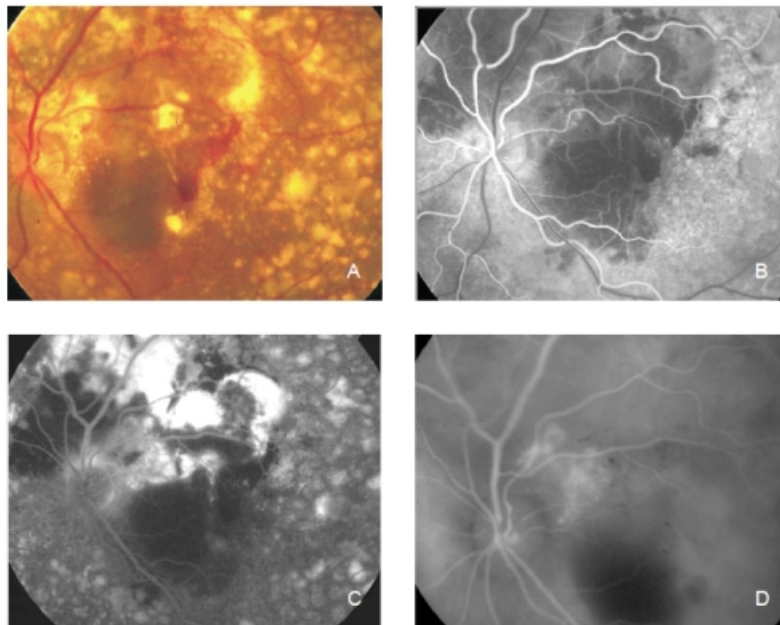


Figure 27 - Polypoidal choroidal vasculopathy.

Although FA can sometimes confirm the diagnosis of PCV, ICG angiography is the choice for imaging this entity.

RPE tears

Although RPE tears can occur spontaneously, it is not uncommon for them to occur after treatment with thermal laser, PDT or antiangiogenic therapy.

RPE tears are commonly related to PEDs, although they have been described in classic lesions too⁽¹⁸⁾.

The detached monolayer of RPE scrolls toward the CNV, leaving a denuded area of choroid exposed.

On FA, the denuded area becomes hyperfluorescent and the scrolled RPE is dark and blocks the underlying fluorescence (Figure 28).

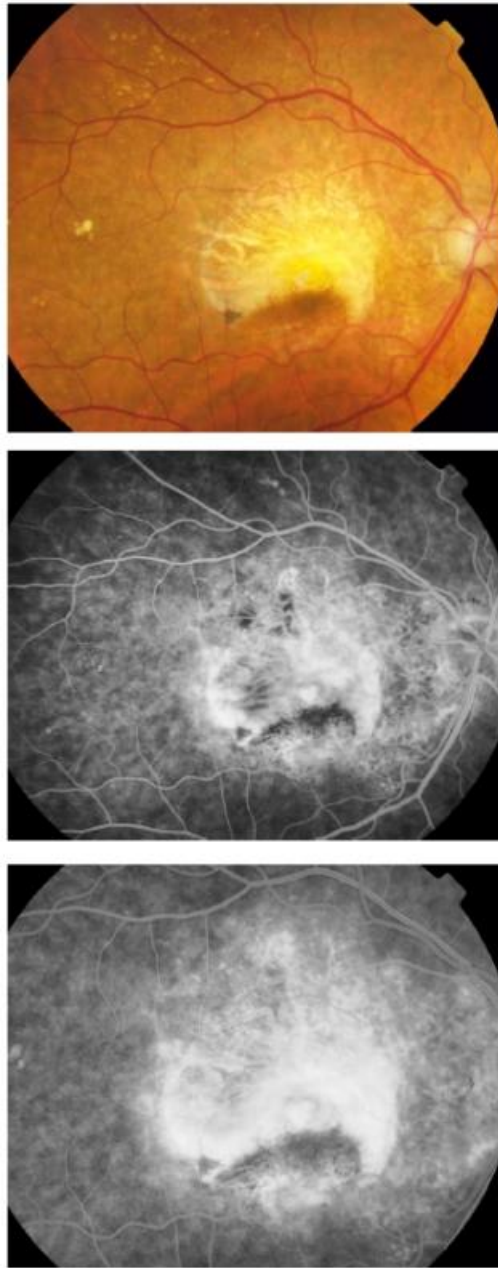


Figure 28 - RPE tear.

Hemorrhagic AMD

FA is not very useful in hemorrhagic forms of macular degeneration since blood blocks the underlying fluorescence (Figure 29).

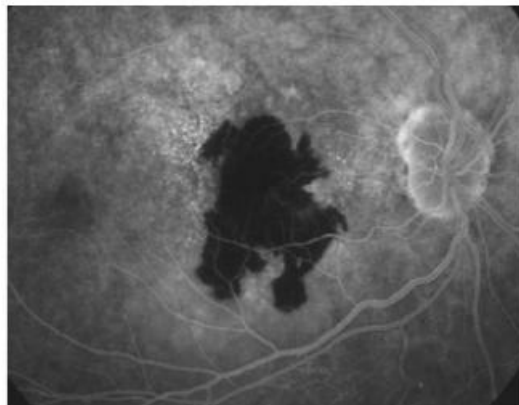
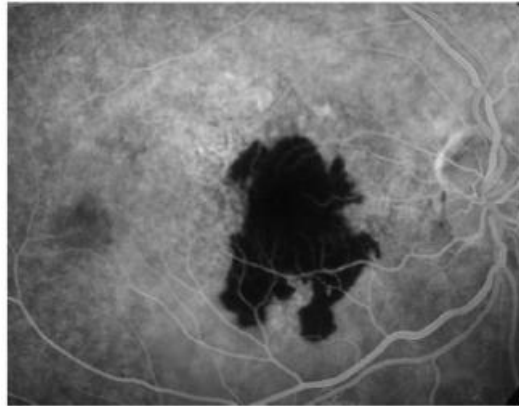
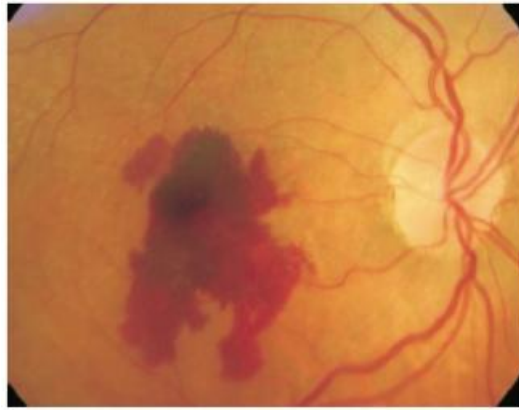


Figure 29 - Hemorrhagic AMD.

ICG angiography can detect the presence of occult CNV.

Disciform scar

A disciform scar is the end-stage manifestation of untreated CNV, namely formed by fibroblasts and inflammatory cells.

Angiographically, it typically shows late staining (Figure 30).

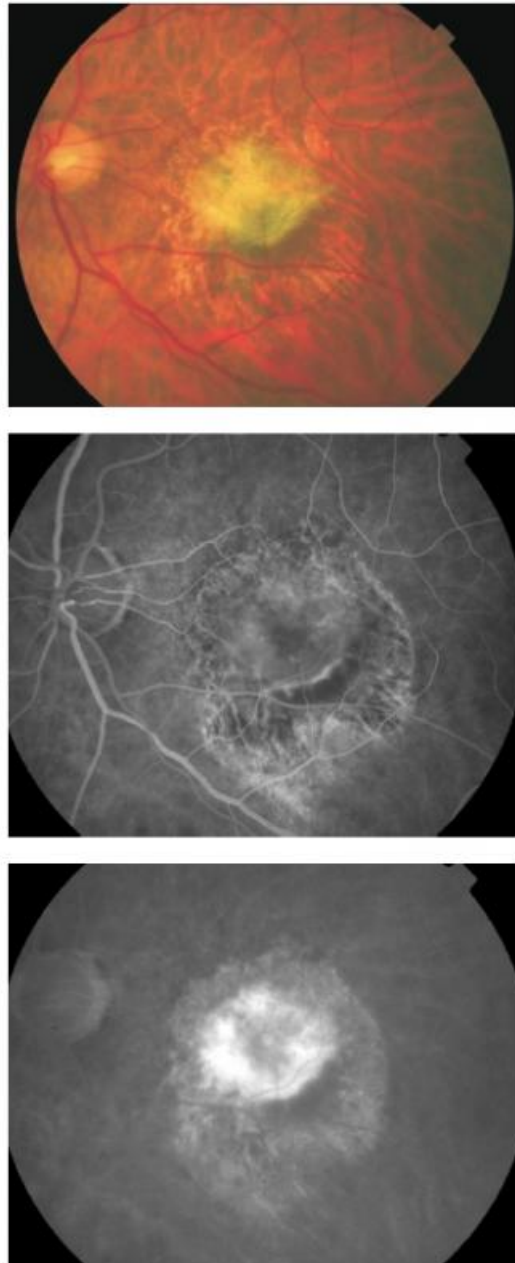


Figure 30 - Disciform scar.

FA for monitoring AMD treatment

In the era of PDT with verteporfin, FA was the gold standard for monitoring the response to treatment⁽¹⁹⁾.

Nowadays, with antiangiogenic therapy, OCT scanning has replaced FA for this purpose since it is highly effective to detect lesion activity and it is a non-invasive procedure⁽²⁰⁾.

However, in some cases FA is still very useful in the evaluation of treated patients.

[>> References](#)

[View PDF](#)